

## Management Dentoalveolar Fracture with Simple Wiring in Mild Head Injury : A Case Report

<sup>1</sup> Fadli Ashar, <sup>2</sup> Indra Hadikrishna, <sup>3</sup> Seto Adiantoro

<sup>1</sup> Oral and Maxillofacial Surgery Department Faculty of Dentistry, Universitas Padjadjaran, RSUP Dr. Hasan Sadikin Bandung, Indonesian, fadli20002@mail.unpad.ac.id

<sup>2</sup> Oral and Maxillofacial Surgery Department, Faculty of Dentistry Universitas Padjadjaran Bandung, Indonesian

<sup>3</sup> Oral and Maxillofacial Surgery Department, RSUP Dr. Hasan Sadikin Bandung, Indonesia

### ARTICLE INFORMATION

Received: May, 9, 2022

Revised: May, 20, 2022

Available online: May, 9, 2022

### KEYWORDS

Interdental Wiring (IDW), Essig Wiring, Dentoalveolar Fracture, Mild Head Injury

### CORRESPONDENCE

Fadli Ashar

Oral and Maxillofacial Surgery  
Department Faculty of Dentistry,  
Universitas Padjadjaran, RSUP Dr. Hasan  
Sadikin Bandung, Indonesia  
fadli20002@mail.unpad.ac.id

### ABSTRACT

*Introduction: Maxillofacial trauma generally involves injury to soft or hard tissue of the face and oral cavity. One of the hard tissue injuries to the oral cavity is dentoalveolar injury such as the luxation and avulsion of the anterior teeth. Management of dentoalveolar injury can be done by reduction and immobilization using splinting. The technique of splinting dentoalveolar fractures in patients with mild head injuries can use simple wiring with consider to short-duration treatments. Case Report: A case report will be reported from the Oral and Maxillofacial Surgery Department of Dr. Hasan Sadikin-Bandung, a 54 year old man came to the Emergency Room of Hasan Sadikin Hospital with bleeding from his mouth due to a motorcycle accident and the patient's face hit the asphalt first. The results of the examination showed that the patient had a dentoalveolar fracture in teeth 11 and 21, had 2 degree luxation and the patient had mild head injuries. Discussion: The patient suffered a mild head injury, confirmed by the Head CT Scan examination and there were injuries to the soft and hard tissues. The patient have soft tissue injuries with vulnus laceratum in the upper and lower lip regions, vulnus laceratum was also found in the gingiva in areas 11-21 and was then treated using suturing the simple interrupted method. The dentoalveolar fracture that affected 11-21 accompanied by 2 degrees of mobility was managed by simple wiring using the essig method. Conclusion: Dentoalveolar fractures in patients with mild head injuries can be used with a simple wiring approach with the essig method, this is taken by considering treatment is simple.*

This is an open access article under the [CC BY-ND](https://creativecommons.org/licenses/by-nd/4.0/) license.



## INTRODUCTION

Maxillofacial trauma were found in about 15% of all emergencies, with 2% involvement of dentoalveolar trauma. (Kosowski et al, 2012; Zhang et al, 2017). Traumatic dental injury can only affect the teeth structures and supporting tissues such as in children who falls in a playground, however, in cases of severe impact it can cause complex multisystem trauma such as in traffic accidents. (Kosowski et al, 2012; Zhang et al, 2017; Chigurupati et al, 2010). Dentoalveolar trauma also found in patients with a history of abuse and sports injury (Kosowski et al, 2012; Zhang et al, 2017; Champbell et al, 2010; Smith et al, 2013). Teeth in the maxillary anterior region were the most affected areas with a percentage of 82% where 64% are found in the central incisors, 15% in lateral incisors, and 3% in canine. Children, adolescents, and young adults are the age group with a high incidence of dentoalveolar fractures, with a ratio of male to female 2-3: 1 (Kosowski et al, 2012; Zhang et al, 2017)

In maxillofacial trauma due to traffic accidents often involves multisystem injuries. Anamnesis is performed in line with physical examination which include mechanism of injury, location and time of incidence, past illness and medications, history of loss of consciousness, nausea and vomiting. (Campbell et al, 2010; Desphande et al, 2014; Smith et al, 2013; Mukozawa, 2011). Evaluation of the potential for aspiration, airway obstructions, and neurological disorders must be carried out before the management of dentoalveolar injuries. (Campbell et al, 2010; Desphande et al, 2014; Smith et al, 2013).

## METHODS

This research method uses descriptive which is a case report. The sample of this study were old male patient with maxillofacial trauma in Hasan Sadikin General Hospital Emergency Department.

## RESULTS

A 54-year old male patient came with bleeding from mouth, Patient was riding a motorcycle at Cikalong area with medium speed, suddenly another motorcycle came from the opposite direction hit him, so he lost his balance and fell down with mechanism his face hit the asphalt first. Patient had History of no using helmet, consciousness, no bleeding from nose, no bleeding from ear. Patient had nausea, vomiting and bleeding from mouth. Then the patient was brought to general hospital at Cikalong Wetan area, but nothing was performed there. Then he was referred to private hospital at Padalarang area, and was performed head CT scan and injection ATS TT, then he was referred to Hasan Sadikin General Hospital Emergency Department for further treatment. Patient had no history of asthma, no diabetes mellitus, no medicine allergy, and had no other systemic diseases.

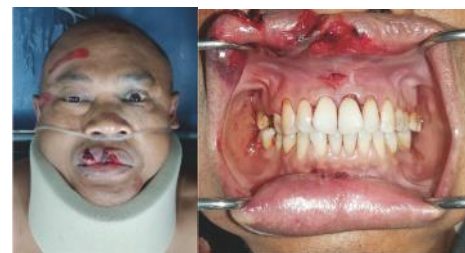

Figure 1. Clinical examination

### Clinical examination results:

- Level of consciousness: compos mentis
  - GCS : E4V5M6
  - Vital sign:
    - o Blood pressure : 110/80 mmHg
    - o Pulse : 88 x/menit
    - o Respiration : 20 x/menit
    - o Temperature : 46.5<sup>0</sup>C
  - Head :
    - o Form :
    - o Face :
- Asymetrical face, oedema and

- hematoma at both eyes and upper lip region
- Eye : non anemic conjungtiva, non icteric sclera
- Oral Examination:
  - Ekstra oral : Asymetrical face, oedema and hematoma at both eyes and upper lip region. Lacerated wound at upper lip region with 3x2x1 cm; 2x2x1 cm in size, irregular edge, muscle based, Abrasive wound at right frontal region.
  - Intra oral : Lacerated wound at upper and lower lips region with 3x2x1cm; 2x2x1 cm in size, irregular edge, muscle based. Lacerated wound at gingiva of teeth 11-21 region with with 2x1x0.5 cm in size, irregular edge, bone based. Lacerated wound at vestibule of teeth 11-21 region with 1x0.5x0.5 cm in size, irregular edge, bone based.
  - Buccal mucosa : Normal
  - Palate : Normal
  - Tongue : Normal
  - Floor of mouth : Normal
  - Tonsils : T1-T1
- Thorax: Symmetrical shape and movement
  - Pulmo : Vesicular beat sound R=L, Ronchi (-/-), Whezzing (-/-)
  - Cor : Regular pure heart sound

- Abdomen : soft and flat, bowel sound (+) Normal
  - Hepar/lien: not palpable, no pain
- Extermity : Warm, Cappillary refill time < 2”

Laboratory finding of hematology have abnormal of Hematokrit 39.9 (Normal 41.5-50.4) and white blood count 22.80 (4.40-11.30) and other parameter is normal. Thorax x-ray, cervical x ray and pelvic x-ray showing normal radiographic picture. Head Ct Scan showing soft tissue at right temporal region, hyperdense mass biconvex at right temporal region an hematosinus at right maxillary sinus region. 3D head ct scan showing discontinuity of left orbital rim bone. USG FAST showing no sign fluid collection in hepatorenal, splenorenal, and vesical urinaria space.

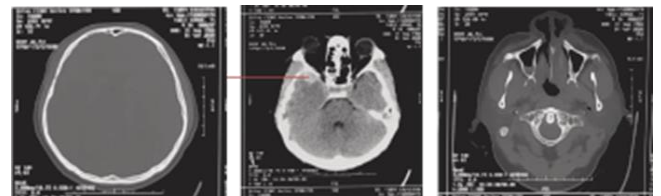

Figure 2. Head CT Scan

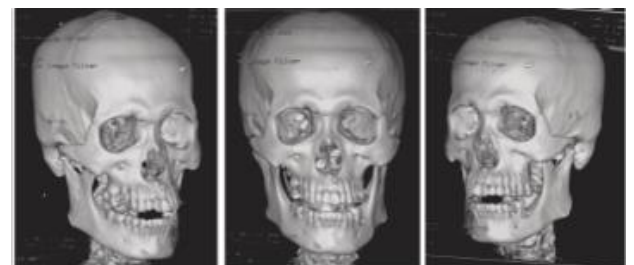


Figure 3. 3D Head CT Scan

### Management

Based on history of the patient during the anamnesis and radiographic evaluation, the patient were consulted to

neurosurgery department and the patient was under observation with no specific treatment. The treatment consisted of debridement and suture of wounds, immobilization of maxillary anterior dentoalveolar fracture with interdental wiring using Essig wiring for fixation teeth 11-21.

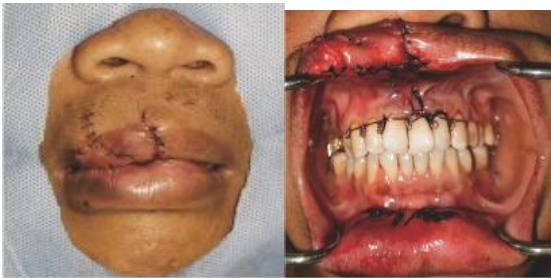

Figure 4. Post treatment after suturing intrupted ekstraoral, intraoral and Simple wiring with essig method

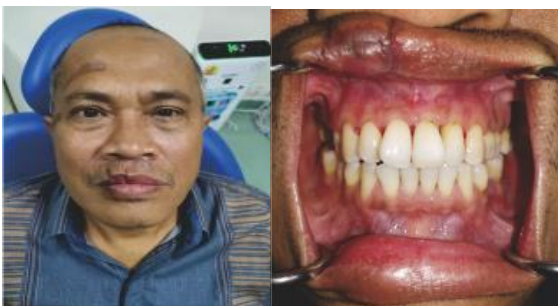

Figure 5. Post operation day xxi

## DISCUSSION

A complete and accurate history taking of the maxillofacial trauma patients is a valuable support in establishing the diagnosis and determining the treatment plans, patient with head injury sometimes difficult to give explanations during the conversations, therefore additional information can be collected from the companion persons such as family, friends, police officer or who else were in the incidence place, and emergency room staffs. (Kosowski et al, 2012; Zhang et al, 2017) Maxillofacial trauma occasionally becomes a complex case, prevention of complications is done by a more thorough examinations and multidisciplinary consultations. (Campbell et al, 2010; Mukozawa et al,

2011). Clinical examinations are performed on all visible regions, including the maxillary and mandibular regions, zygomatic region, orbital region, frontozygomatic suture, zygomatic process, nose, ear, jaw joint region, and the entire intraoral region (Zhang et al, 2017; Campbell et al, 2010; Smith et al, 2013).

Based on the history, the patient experienced complaints of pain in the head, gums and teeth due to trauma from the motor fall. Facial trauma can cause increased secretions or tooth extraction which can add to the airway problem (Kosowski, 2012; Smith, 2013). However, these patients have been treated previously at the community health service, therefore the airway inspections and handling were not conducted further. The patient had history of bleeding from mouth, nausea and vomiting immediately after the accident, therefore consultation to neurosurgery department was made before the definitive treatment, general examinations was performed included history of allergy, blood pressure and cardiac function, routine blood count test and coagulation, history of other illnesses suffered before trauma (Kosowski, 2012; Smith, 2013). Radiographic examination was carried out to clarify the clinical diagnosis, determining the location of the fracture and other conditions in the head region, CT- Scan were performed to assess the patient's neurological disorders (Kosowski, 2012; Smith, 2013; Adesina et al, 2016; Smith, 2013). Informed consent was done before the procedure according to the procedure, by installing Essig for fixation teeth 11-21.

## CONCLUSION

Trauma on maxillofacial region is caused by a variety of factors, ranging from traffic accidents, physical violence, from falls, sports injuries to injury from firearms. Maxillofacial trauma due to traffic accidents often involves multisystem injuries resulting in complications. Careful and complete examination and multidisciplinary consultations can prevent complications of maxillofacial

trauma. Radiological examination with simple imaging or CT-Scan are needed to confirm the diagnosis and treatment plans. Dentoalveolar fractures in patients with mild head injuries can be used with a simple wiring approach with the essig method, this is taken

## REFERENCE

- Adesina, Oluwafemi Adewale , Adeyemi, Akinwale Efunkoya, Omeje, Kelvin Uchenna , Paul Ikhodaro Idon. (2016). Postoperative complications from primary repair of cleft lip and palate in a semi-urban Nigerian teaching hospital. *Niger Med J.* May-Jun; 57(3): 155–159.
- Campbell, Andrew, Bernard J. Costello, Ramon L. Ruiz. (2010). Cleft Lip and Palate Surgery: An Update of Clinical Outcomes for Primary Repair. *Oral Maxillofacial Surg Clin N Am* 22 43–58
- Chigurupati, Radhika, Heggie, Andrew, and Bonanthaya, Krishnamurthy. (2010). Cleft Lip and Palate : An Overview. *Oral and Maxillofacial Surgery* ed 1
- Deshpande, Gaurav Shekhar, Campbell, Alex, Rasika Jagtap, Carolina Restrepo, Hannah Dobie, Henry Tait Keenan, Hiteswar Sarma. (2014). Early Complications After Cleft Palate Repair: A Multivariate Statistical Analysis of Patients. *J Craniofac Surg*;25: 1614–1618
- Kosowski, Tomasz R., Weathers, William M., Erik M. Wolfswinkel, Ridgway, Emily B. (2012) Cleft Palate. *Semin Plast Surg*;26:164–169
- Mukozawa, Mai, Kono, Takashi, Fujiwara, Shigeki, Ko Takakura. (2011). Late onset tongue edema after palatoplasty. *Acta Anaesthesiologica Taiwanica*;49: 29-31
- Murthy Jyotsna . (2014). Complications of cleft palate repair and how to avoid them. *Journal of Cleft Lip Palate and Craniofacial Anomalies* January-June / Vol 1 / Issue 1
- Perry, Percy Rossell. (2015). Review Article Flap Necrosis after Palatoplasty in Patients with Cleft Palate. *Hindawi Publishing Corporation BioMed Research International* Volume, Article ID 516375, 14 pages <http://dx.doi.org/10.1155/2015/516375>
- Rajesh, MC , Saji Kuriakose, Jayanth Sukumar, EK Ramdas.(2013) Massive lingual swelling following cleft palate repair. *J Anaesthesiol Clin Pharmacol.* Apr-Jun; 29(2): 262–263.
- Shaye, David, Carrie Liu, Travis T, Tollefson. (2015). Cleft Lip and Palate An Evidence Based Review. *Facial Plast Surg Clin N Am* 23 357–372
- Siew Min Keh, Mohammad Hasan, Vamsidhar Vallamkondu, Muhammad Shakeel. (2020). Management of acute tongue swelling. *Heighpubs Otolaryngol Rhinol.*; 4: 012-017
- Smith, Sefhj Abdullah, A Moores, DM Wyne. (2013). Post-operative respiratory distress following primary cleft palate repair. *The Journal of Laryngology & Otology*: 127, 65–66
- T M. Abdel-Aziz, A. Ahmed, N. Naguib, M. I. Abdel-Khalik. (2012) The effect of steroid injection of the tongue base on reducing postoperative airway obstruction in cleft palate repair. *Int. J. Oral Maxillofac. Surg.*; 41: 612–615

Xiaodong Zhao, Xuezhong Yu. (2019). Expert consensus on nebulization therapy in pre-hospital and in-hospital emergency care. [Ann Transl Med](#). Sep; 7(18): 487

palate repair in syndromic and non-syndromic children: a systematic review protocol. *Syst Rev* 6, 52. <https://doi.org/10.1186/s13643-017-0438-2>

Zhang, [Zach](#), Stein, [Michael](#), Mercer, [Nigel](#), [Claudia Malic](#). (2017). Post-operative outcomes after cleft